

# PERCUTANEOUS GASTROSTOMY



# PERCUTANEOUS GASTROSTOMY

**Dr. H. Negila**

## PERCUTANEOUS GASTROSTOMY

# INDICATIONS

- Patients who need prolonged nutritional support include:
  - \*Head, Neck and esophageal carcinoma
  - \*Chronic conditions such as cystic fibrosis and congenital heart disease
- \*Bowel decompression
- \*Some neurologic disease
- \*Swallowing disorders and esophageal strictures

## PERCUTANEOUS GASTROSTOMY

# CONTRE INDICATIONS

### ABSOLUTE:

Gastric varices

Total gastrectomy

Uncorrectable coagulopathy

### RELATIVE:

Ascites

Partial gastrectomy

Coagulopathy

Overlying colon

Inability to pass a nasogastric tube

## PERCUTANEOUS GASTROSTOMY PREPARATION

- Informed consent
- NG tube placement
- 300 ml oral barium in the evening
- Intravenous access
- Analgesia
- Glucagon

PERCUTANEOUS GASTROSTOMY

# COMPLICATIONS

•Major:

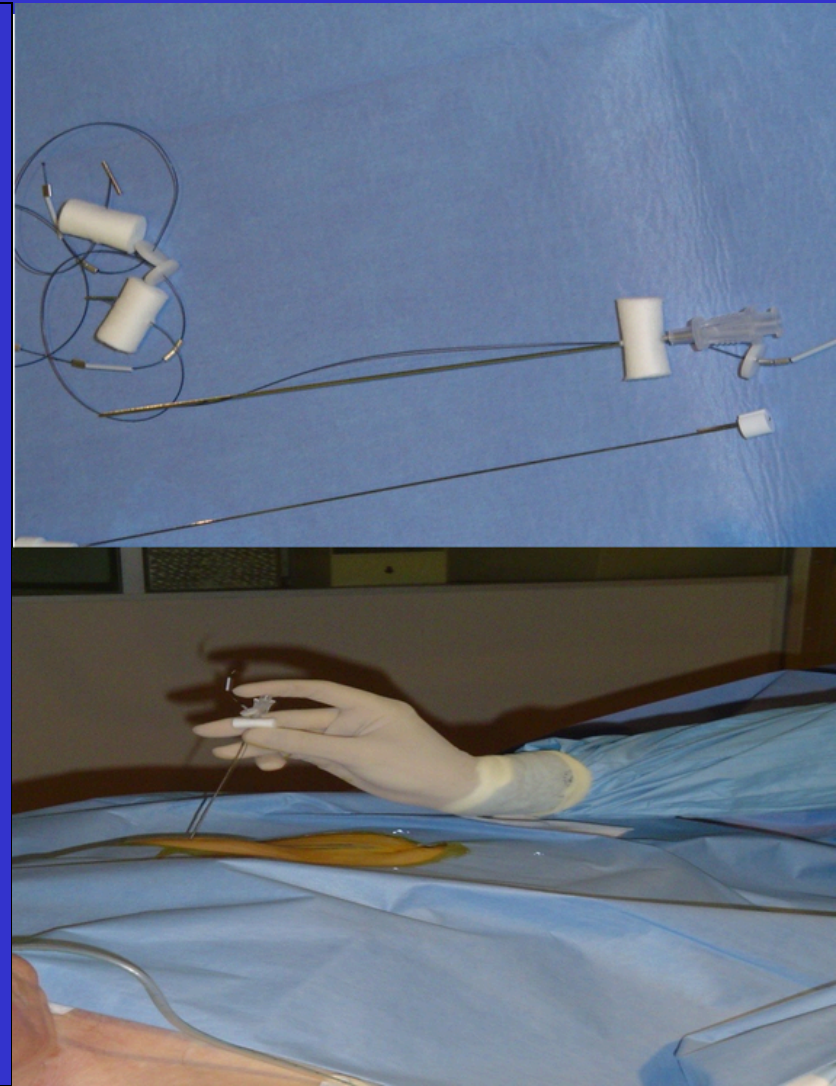
- Major infection and septicemia
- Perforation
- Hemorrhage
- Aspiration
- Dislodgement of the tube

.Minor:

- Wound infection
- Dislodged or leaking tube

PERCUTANEOUS GASTROSTOMY  
T-fasteners

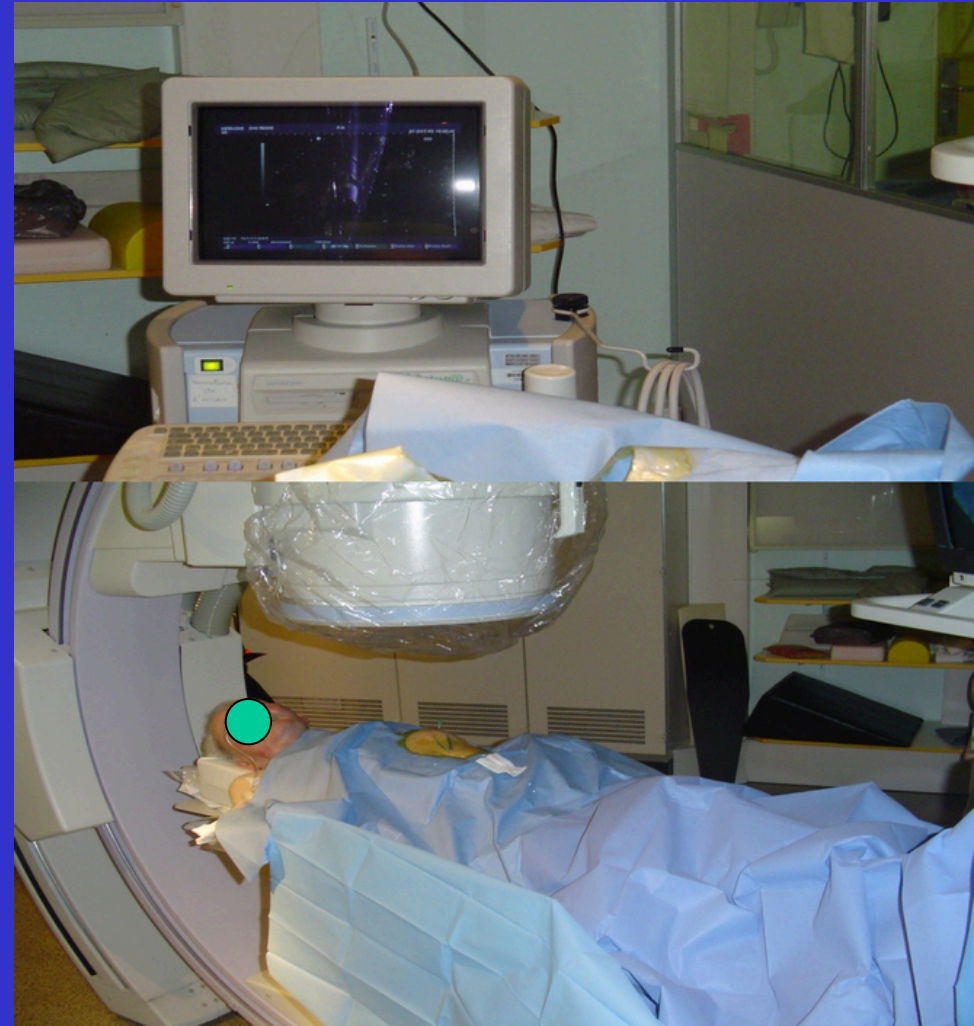- T-fasteners



## PERCUTANEOUS GASTROSTOMY

# FIRST STEP

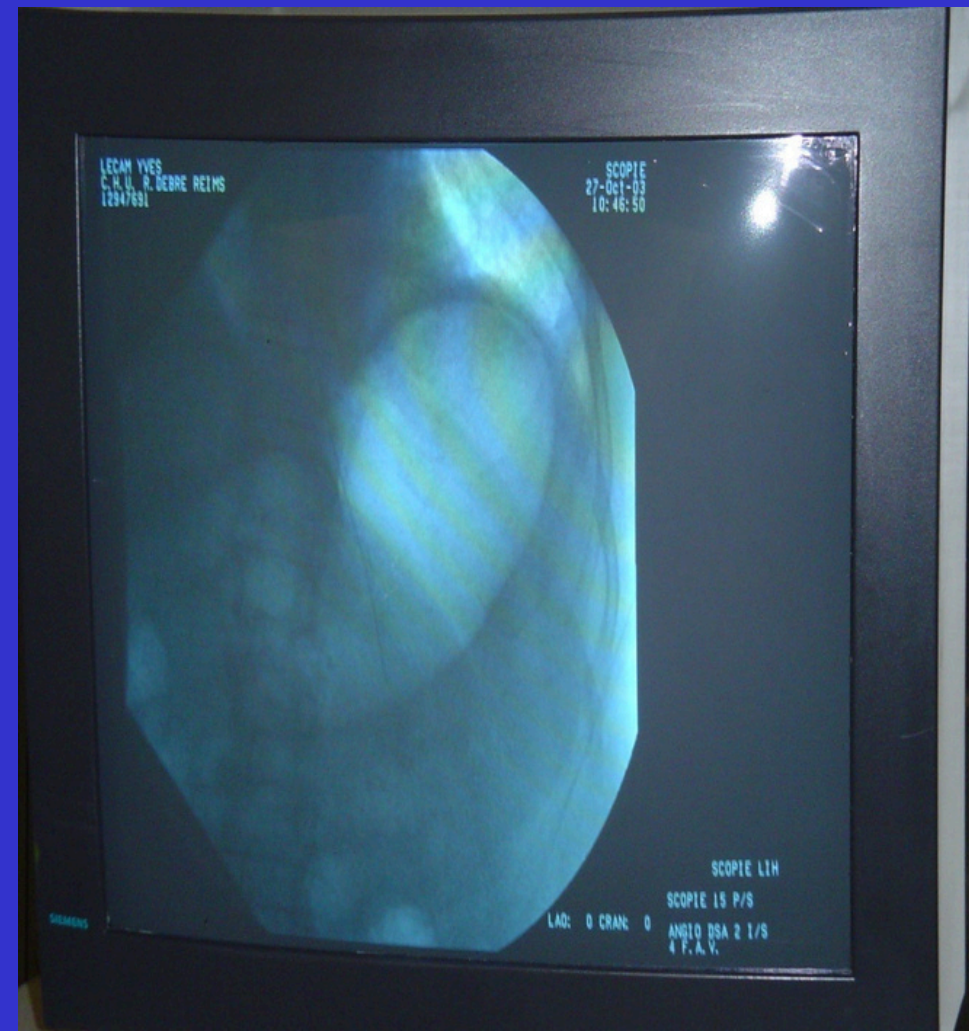
- Mark the position of left hepatic lobe by ultrasound and injection of 1 mg of glucagon



# PERCUTANEOUS GASTROSTOMY

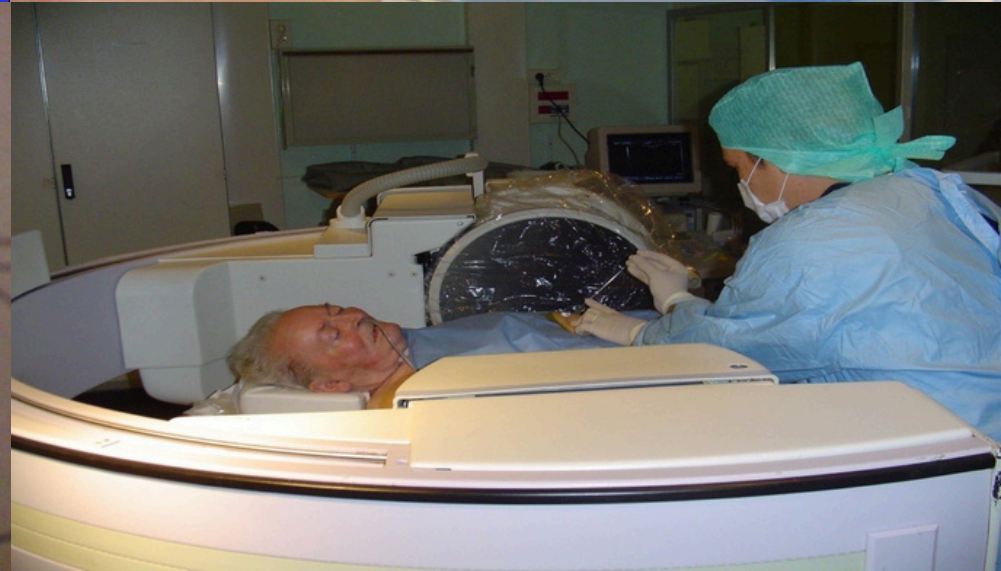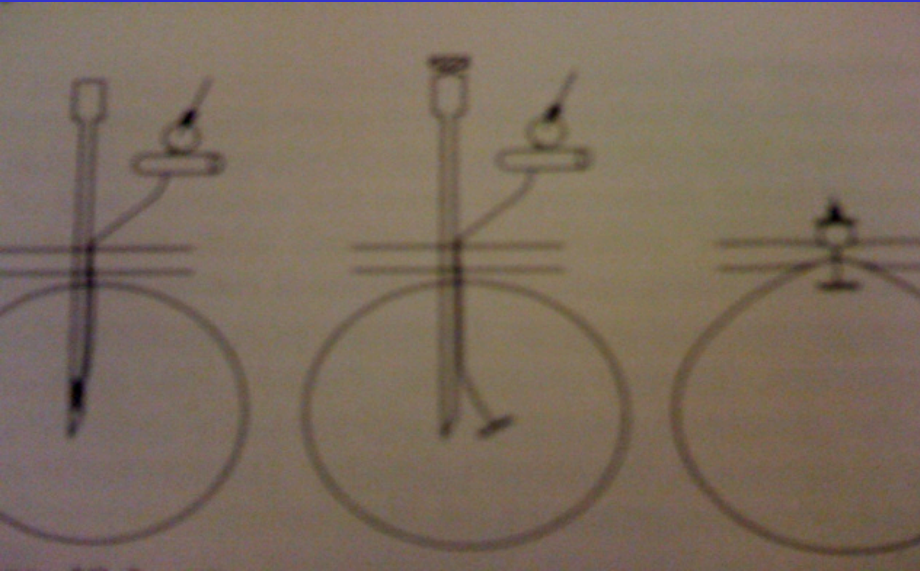
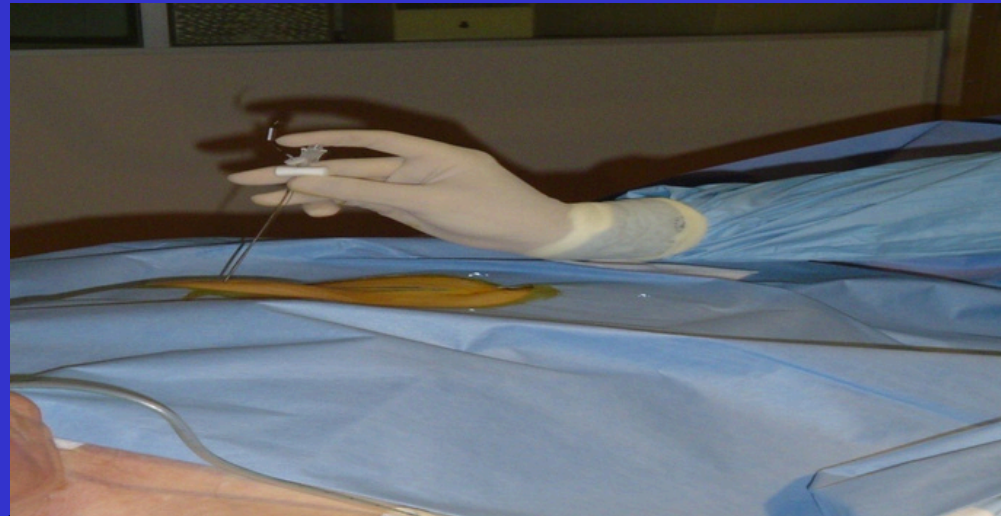
## SECOND STEP

- Gastric distension by injection of air in the NG tube



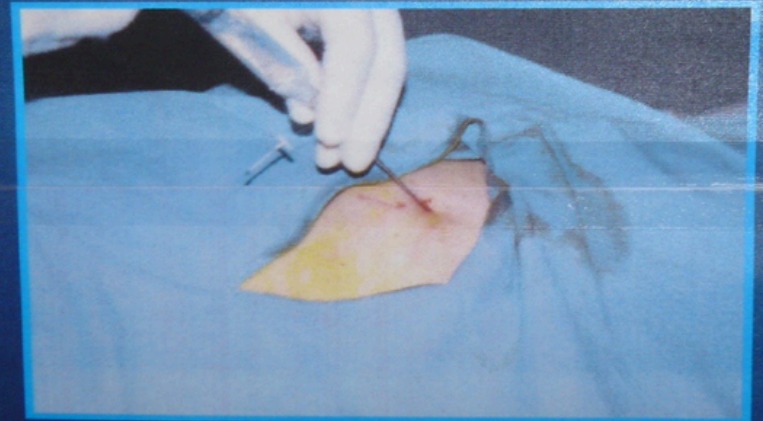
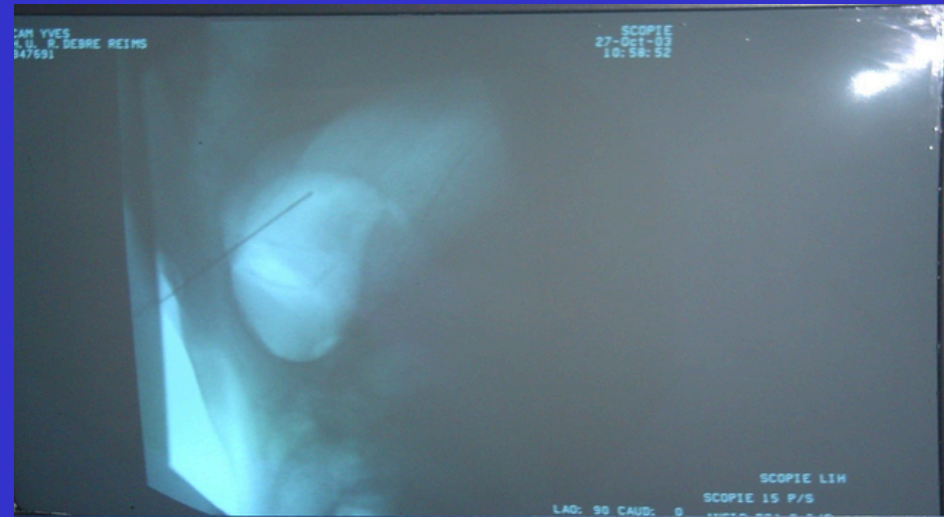
PERCUTANEOUS GASTROSTOMY  
THIRD STEP

- Gastroplexy using the T-fastener



# PERCUTANEOUS GASTROSTOMY VERIFICATION

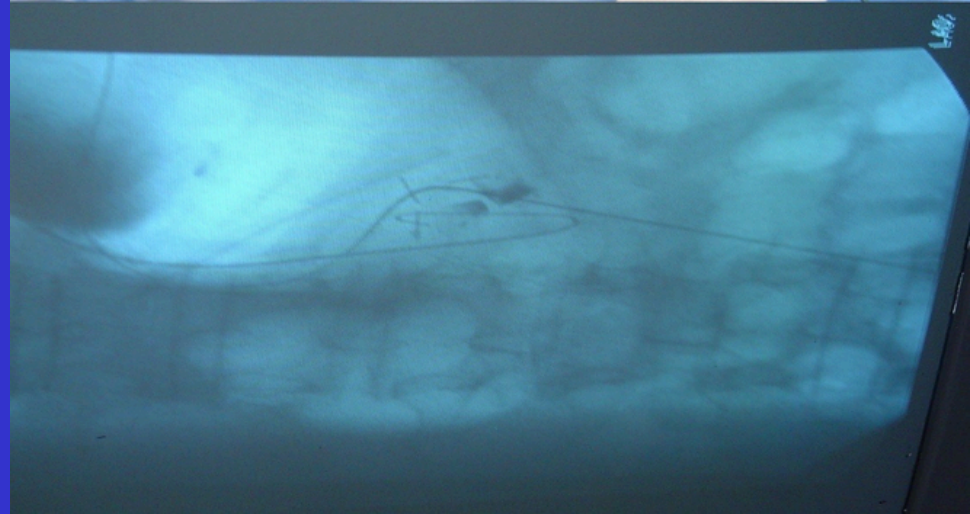
- Injection of contrast to ensure the right position of the needle inside the stomach



## PERCUTANEOUS GASTROSTOMY

# Seldinger Technique

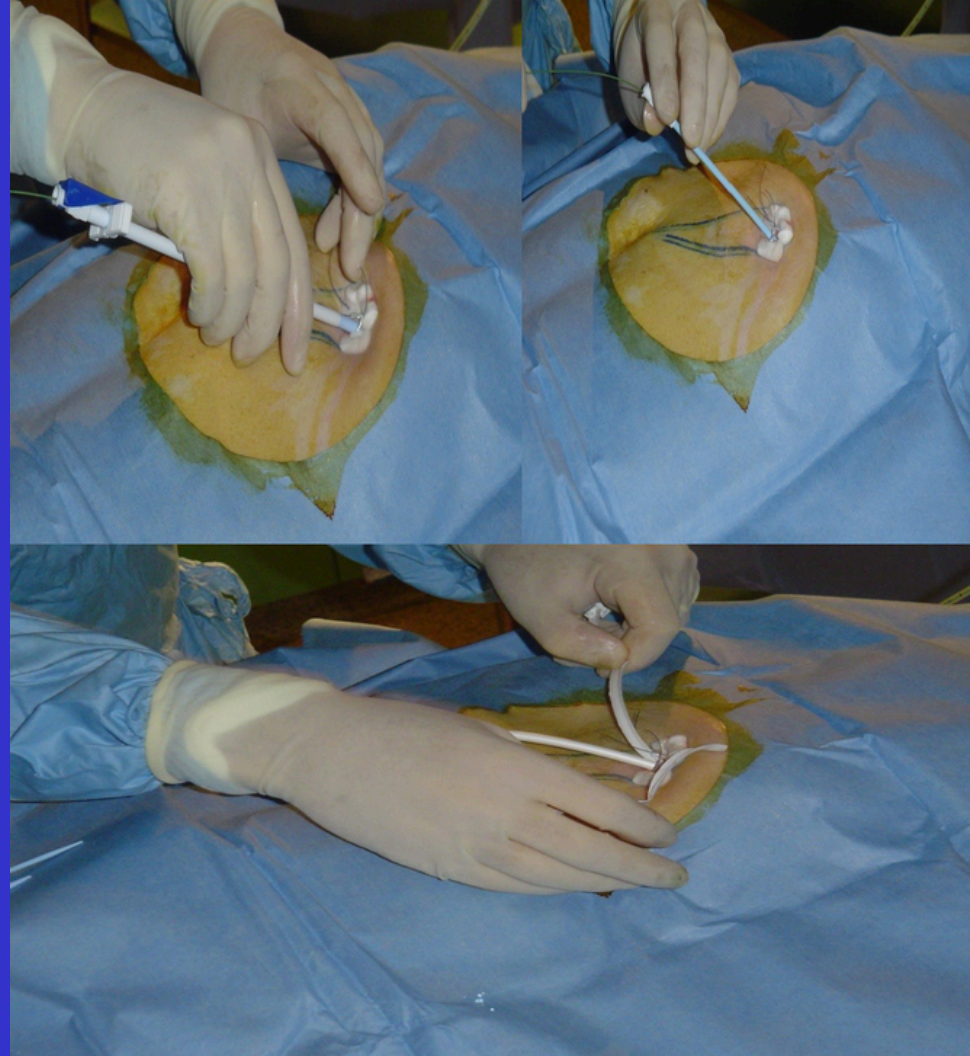
- Using a guidewire to introduce inside the needle



## PERCUTANEOUS GASTROSTOMY

# DILATATION

- Of the orifice by guide( 9F, 14F, 16F ) or using of Baloon



PERCUTANEOUS GASTROSTOMY  
AT THE END

- Control the position of umbrella

